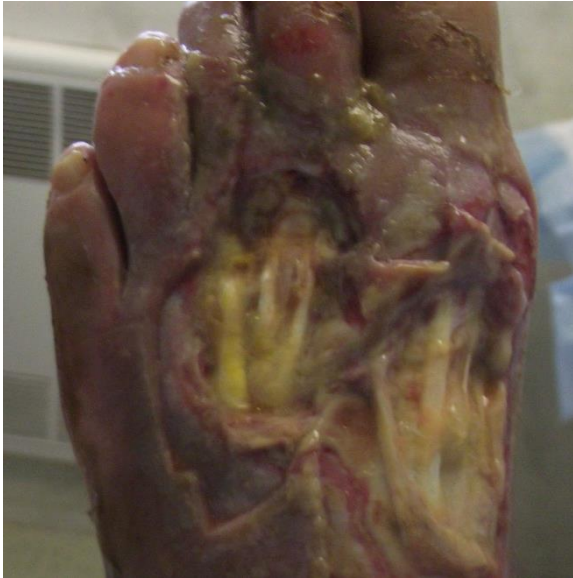

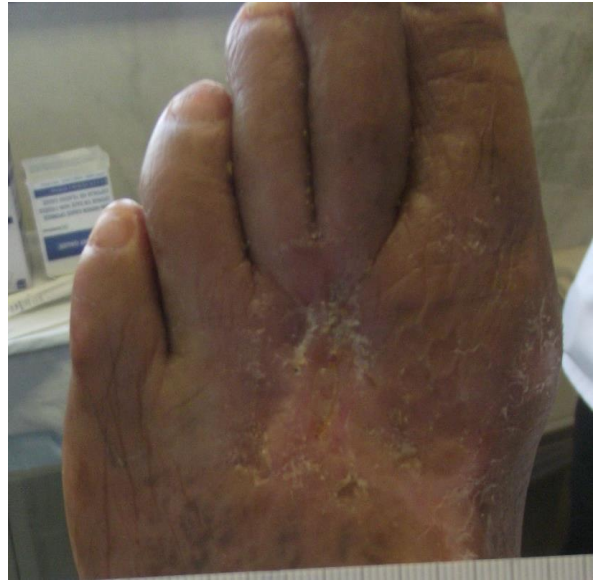WALKSSM Wound Centers Healing Portfolio

77 year old female with feral cat bite. Healed within 6-8 months with revascularization, aggressive debridement and aggressive wound care

Before

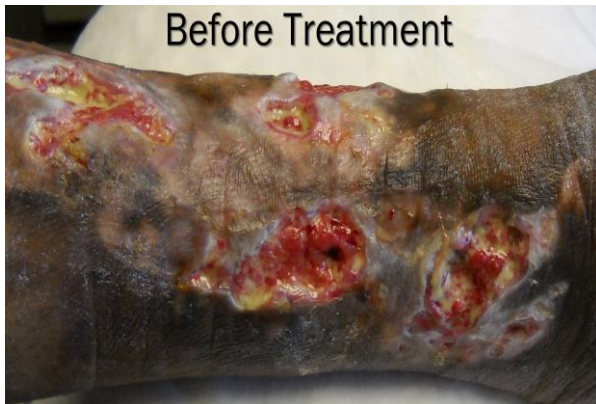

After

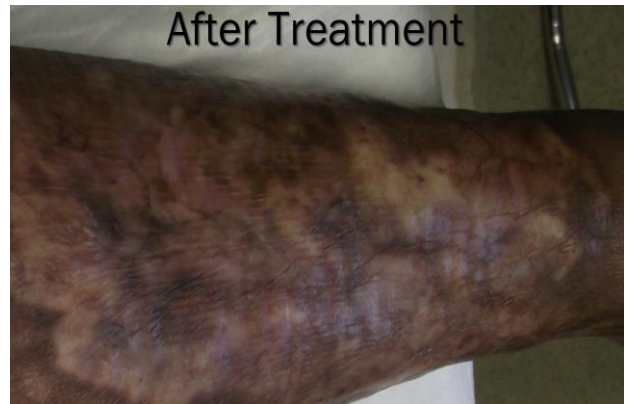


81 year old female with multiple venous stasis ulcers and severe venous reflux. Healed within 9 -10 months with EVLT, compression, aggressive debridement and aggressive wound care

Before

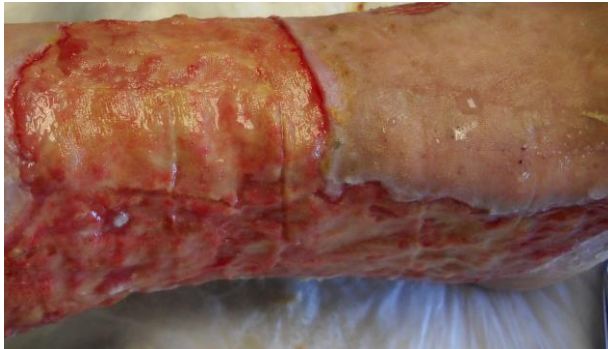

After

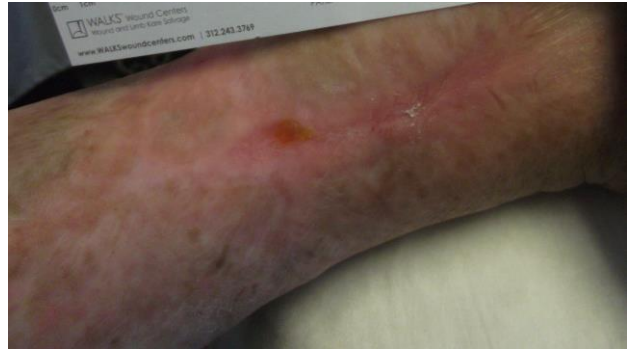

47 year old female with venous stasis ulcer. Healed within 7 months with EVLT, compression, aggressive debridement and aggressive wound care

Before

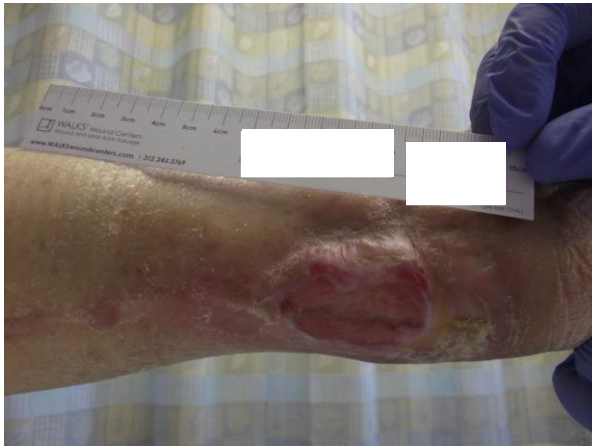

After

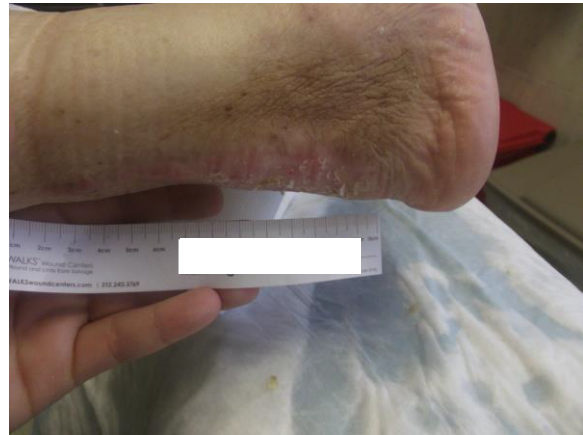

82 year old female with post-operative ulcer, originally with cellulitis and scheduled for a BK amputation. Healed within 10 months with aggressive I&D, aggressive debridement and aggressive wound care

Before



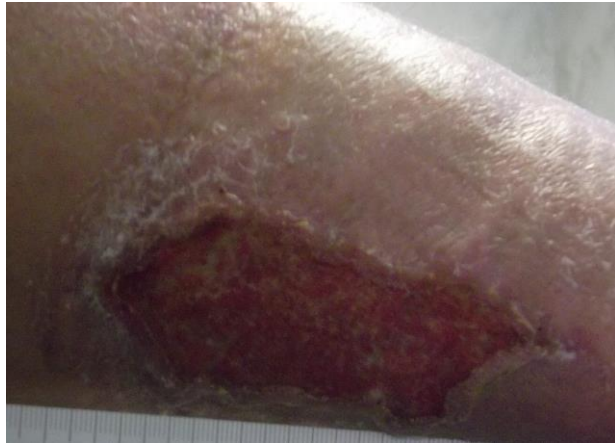After



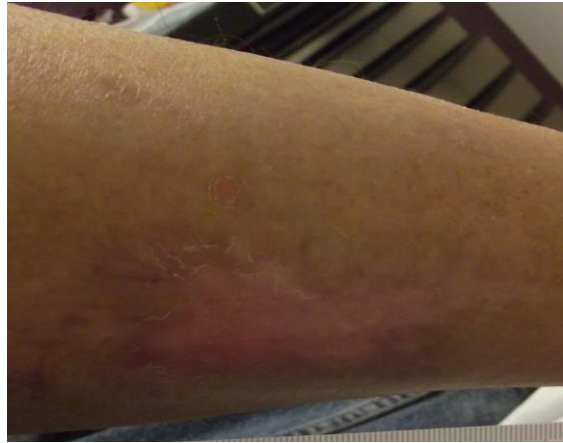

57 year old male with work related injury. Healed within 9 months with aggressive debridement and aggressive wound care

Before

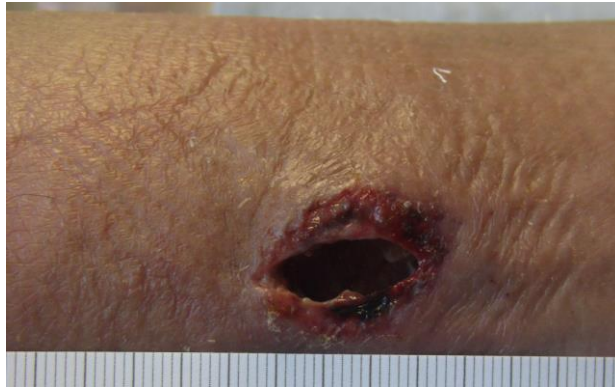

After

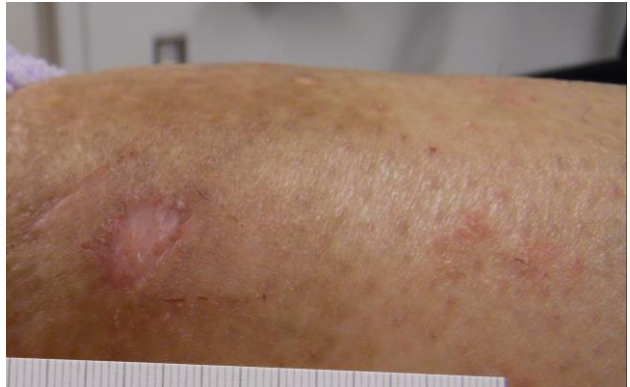

47 year old female with venous ulcer, suffered DVT from airline travel. Healed within 1 1/2 months with aggressive debridement and aggressive wound care

Before



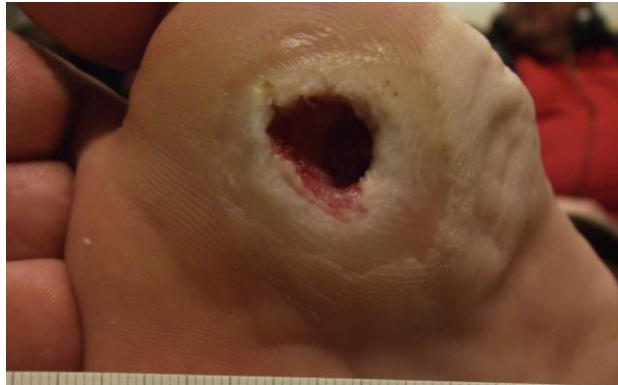After



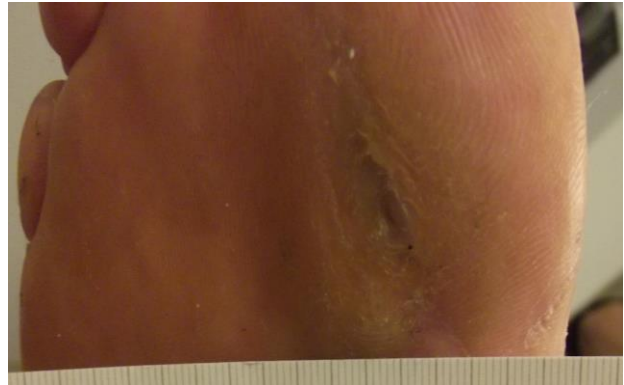

47 year old male with DFU (pressure ulcer), severe cellulitis and osteomyelitis. Healed within 7 months with aggressive I&D and secondary surgical wound closure.

Before

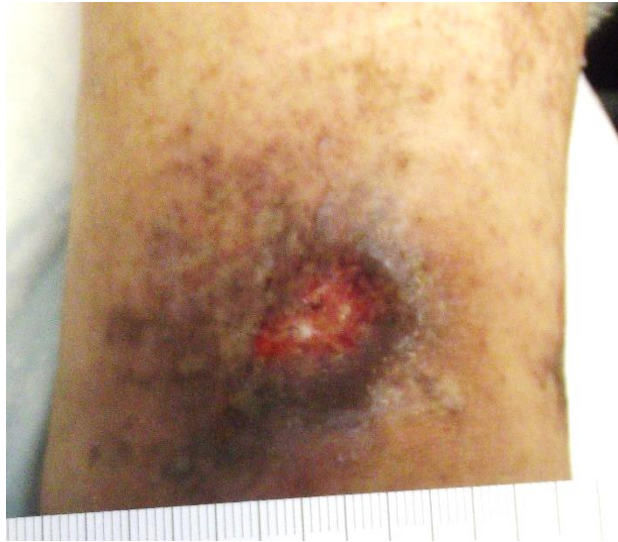

After

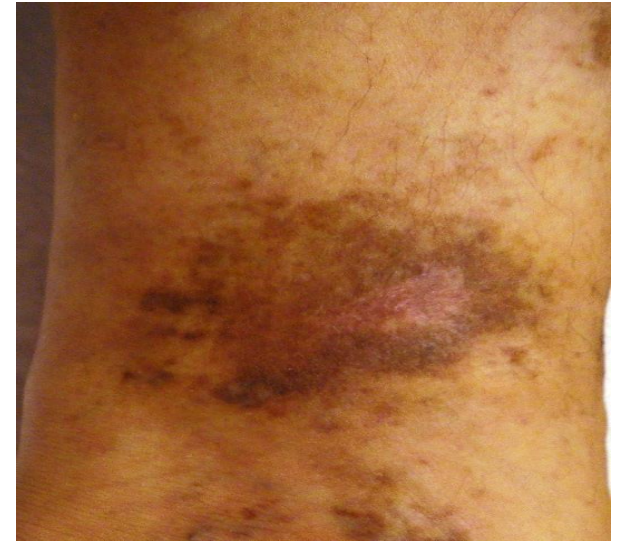

49 year old female with DFU (trauma from a fall). Healed within 2 months with aggressive debridement and aggressive wound care

Before



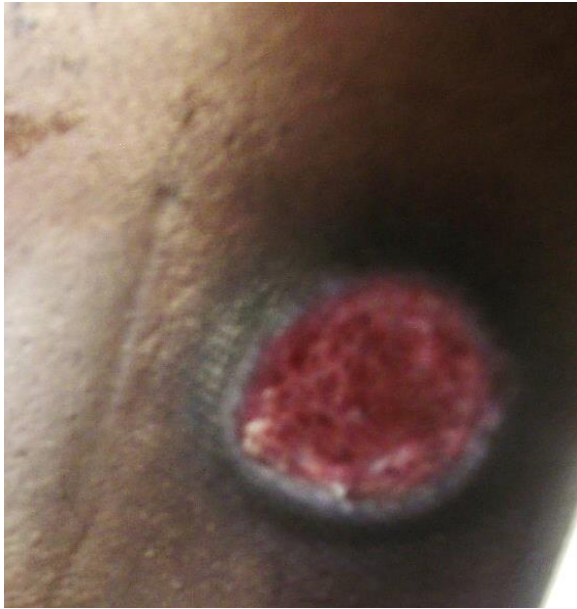After



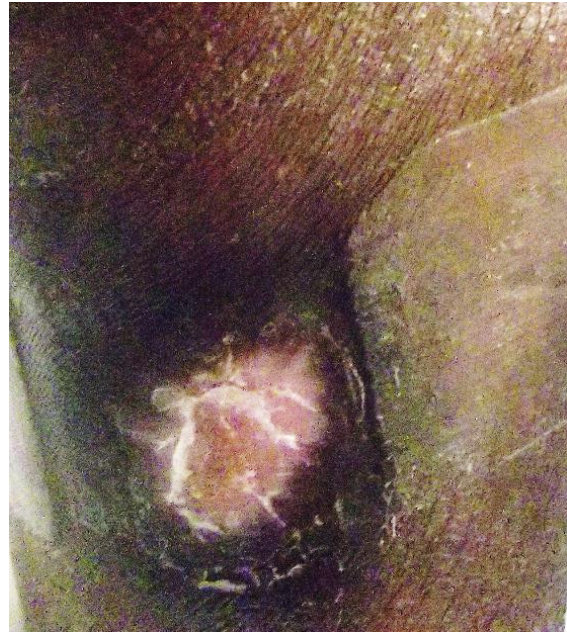

59 year old female with venous stasis ulcer. Healed within 2 ½ months with aggressive debridement, aggressive wound care and compression.

Before

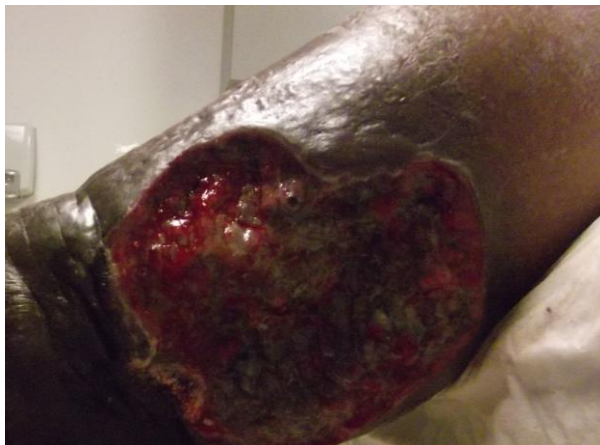

After



55 year old female with venous stasis ulcer. Healed within 5 months with aggressive debridement, aggressive wound care and compression.

Before



After

